

Absent pulmonary valve syndrome: prenatal cardiac ultrasound diagnosis with autopsy correlation

S. Philip^{1*}, M. Varghese¹, K. Manohar^{1,2}, and K.M. Cherian^{1,2}

¹Fetal Cardiac Program, Division of Pediatric Cardiology, St Gregorios Cardio-Vascular Centre, Dr K. M. Cherian Heart Foundation, Parumala, Pathanamthitta Dt., Kerala 689626, India; and ²Department of Pediatric Cardio-Thoracic Surgery, Frontier Life Line Hospital, International Center for Cardio-Thoracic and Vascular Diseases, Ambathur Estate Road, Chennai, India

Received 20 June 2011; accepted after revision 3 August 2011; online publish-ahead-of-print 6 September 2011

Absent pulmonary valve syndrome (APVS) is a rare conotruncal anomaly consisting of a severely hypoplastic pulmonary valve with annular stenosis, aneurysmal dilatation of main pulmonary artery with dilatation of one or both pulmonary artery branches, and a ventricular septal defect. Here, we report a prenatal echo diagnosis of APVS in a 27-year-old primi gravida at 20 weeks of gestation confirmed on fetal autopsy. A 'bow tie'-like hypoechoic shadow in fetal cardiac ultrasound observed by us in a modified four-chamber view was suggestive of aneurysmal dilatation of branch pulmonary arteries. The consequences of continuation of pregnancy including immediate neonatal complications and possible medical and multistaged surgical interventions were well explained. Parents opted for medical termination of pregnancy. Autopsy findings of the fetus were consistent with the prenatal echo diagnosis of APVS. The presence of patent ductus arteriosus seen in the autopsy may be the cause of severe heart failure evidenced by the abnormally large congested liver, dilated right heart chambers, and tricuspid valve annulus. We infer that the prenatal diagnosis of APVS may be possible with a high degree of accuracy with characteristic fetal echocardiographic findings such as 'bow tie'-like or 'ballooning'-like shadows observed in this case. The presence of ductus confirms definite fetal loss and the parents can be counselled accordingly. However, when the ductus is absent, decision-making is difficult as the fetus is going to survive.

Keywords Absent of pulmonary valve syndrome • Pulmonary artery dilatation • Prenatal cardiac diagnosis • Tetralogy of Fallot

Introduction

Cheevers¹ reported a case of absent pulmonary valve syndrome (APVS) in 1847. APVS is a rare conotruncal anomaly in which the pulmonary valve is absent or rudimentary, usually associated with a malalignment type of ventricular septal defect and stenotic pulmonary annulus.² It is considered as a variant of tetralogy of Fallot (TOF) and ~30% of these children have absent ductus arteriosus.^{2,3} The presence of ductus arteriosus in this anomaly will cause severe pulmonary regurgitation leading to congestive heart failure and fetal loss.⁴ Here, we report a case of the prenatal diagnosis of APVS at 20-week gestation, with autopsy correlation.

Case report

A 27-year-old primi was referred for fetal echocardiogram at 20 weeks of gestation in view of atrial enlargement noted elsewhere

on routine ultrasound examination. Fetal echocardiogram obtained by various conventional and modified views showed normal situs, levocardia, normal systemic and pulmonary venous drainage, and large subaortic ventricular septal defect with 50% overriding of aorta (*Figure 1A*). M-mode measurement values of fetal heart were compared with normal reference ranges for gestational age with corresponding percentile showed mitral valve 4 mm (50th), tricuspid valve 5.2 mm (90th), mitral valve orifice/tricuspid valve orifice ratio 1.3 (>95th), right pulmonary artery 4.8 mm, left pulmonary artery 8.4 mm (>95th), and width of right and left ventricles 8.8 mm (>95th) and 7.9 mm (>80th), respectively. The cardio-thoracic ratio (0.54) was more than 95th percentile, indirectly gives high central venous pressure. Great artery relationship was normal, significant pulmonary artery stenosis and regurgitation was noted by continuous-wave Doppler interrogation across the pulmonary annulus (*Figure 1B*). A 'bow tie'-like hypoechoic shadow observed by us at the left side of the heart in a

* Corresponding author. Tel: +91 479 3292125, Fax: +91 479 2311008, Email: tfcsaji@yahoo.co.in or sajitfc@hotmail.com

Published on behalf of the European Society of Cardiology. All rights reserved. © The Author 2011. For permissions please email: journals.permissions@oup.com

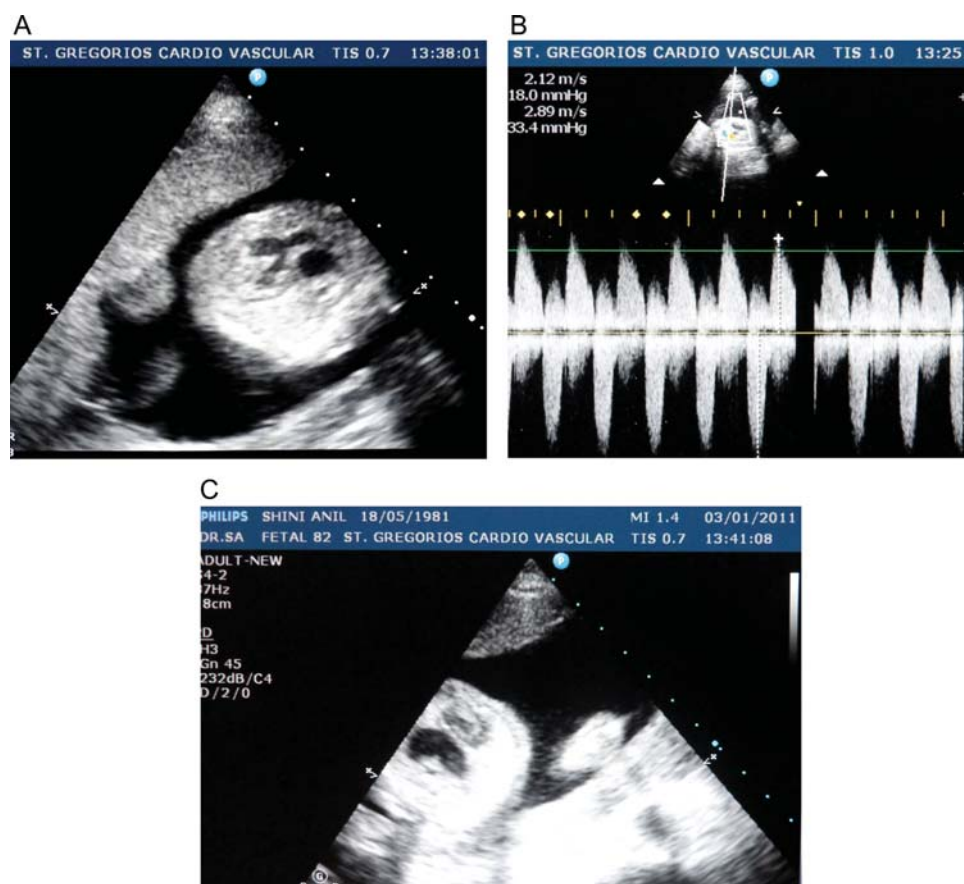


Figure 1 (A–C) Two-dimensional fetal cardiac ultrasound images at 20 weeks of gestation. (A) Modified four-chamber view showed overriding of aorta, large subaortic ventricular septal defect with ballooning-like hypoechoic shadow of dilated left pulmonary artery at the left side of aorta. (B) Continuous-wave Doppler tracing showed a significant stenotic and regurgitant gradient across the pulmonary annulus. (C) Modified four-chamber view with further angulations showed 'bow tie'-like hypoechoic shadow signifying aneurismal dilatation of both peripheral pulmonary arteries.

modified four-chamber view obtained by tilting the probe posteriorly was suggestive of dilated branch pulmonary arteries (Figure 1C). These findings on fetal echocardiogram were consistent with APVS.

Counselling was done, regarding the consequences of continuation of pregnancy including the possibility of intrauterine complications endangering the pregnancy such as congestive heart failure and fetal hydrops. Immediate neonatal complications, such as respiratory distress due to the bronchial compression of the dilated pulmonary artery, and need of multistage surgical procedures were also explained. The parents opted for the medical termination of pregnancy.

Autopsy of the fetus was performed with the consent of the parent. The situs was normal and the size of the fetus and fetal heart measured 240 and 27 mm, respectively. The liver was enlarged, congested, and extending up to the left side of the abdomen (*Figure 2A*). Intra-cardiac autopsy findings included aneurismal dilatation of pulmonary arteries and its branches with preferential aneurismal dilatation of left pulmonary artery measuring

7 mm in diameter (*Figure 2B*), left oriented infundibulum, stenotic pulmonary annulus (2 mm) (*Figure 2C*), large conoventricular septal defect (9 mm) (*Figure 2D*), and ductus arteriosus (*Figure 2E*). Enlarged liver in the presence of dilated right heart chambers and tricuspid valve (*Figure 2F*) indicated severe intrauterine congestive heart failure and impending hydrops.

Discussion

Conotruncal anomalies can be diagnosed in prenatal life by fetal echocardiogram with a high degree of accuracy. Difficulties in defining the spatial relationship of great arteries limit the accuracy of diagnosis in some instances.⁵ APVS can be suspected when we see any associated echocardiographic findings like aneurysmal dilatation of pulmonary arteries, and its branches appearing as 'bow tie'- or 'balloon'-like hypoechoic shadow as we have observed (Figure 1A and C). The presence of both stenotic and regurgitant Doppler gradient at the pulmonary annulus differentiate from uncomplicated TOF (Figure 1B). Studies conducted by Andrew

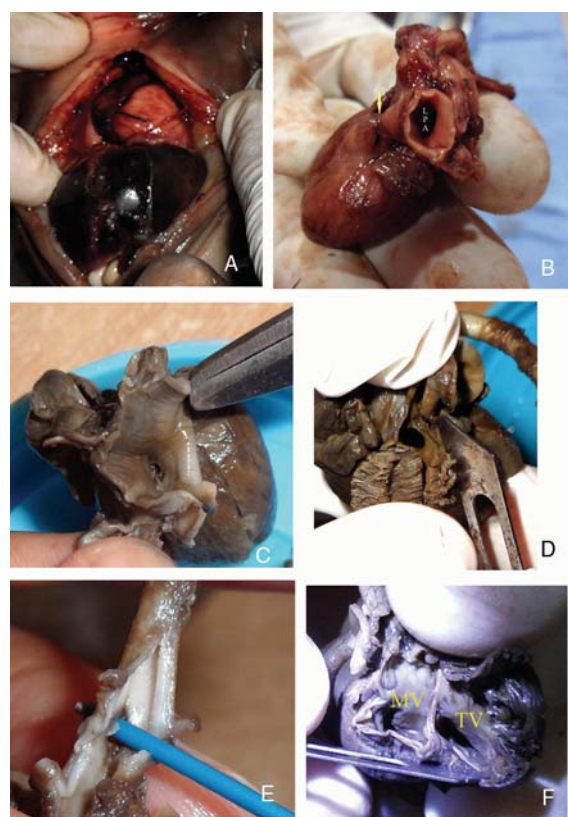


Figure 2 (A–F) Autopsy findings at 20-week gestation. (A) Midline cut open view showed normal situs, levocardia, and congested large liver extending to the left side of the abdomen. (B) Specimen of fetal heart showed preferential aneurismal dilatation of left pulmonary artery (7.5 mm) with pulmonary annular narrowing with arrow indicated. (C) Open view of main pulmonary artery showed stenotic pulmonary annulus measuring 2 mm. (D) Pulmonary artery transection towards right ventricular out flow tract showed large conoventricular septal defect. (E) Open view of arch of aorta showed ductus arteriosus measuring 1.2 mm with probe *in situ*. (F) Transverse section at the atrioventricular level showed dilated tricuspid valve annulus (TV).

*et al.*⁶ showed that conotruncal anomalies pose poor prognosis for the fetus and 64% of the fetuses with a prenatal diagnosis of conotruncal anomalies died except in cases of uncomplicated TOF. The mortality is comparable with the Allan *et al.*⁵ study which showed mortality ranged from 50 to 65%. In our autopsy study, we found that the liver was abnormally large and congested with tricuspid valve annular dilatation, signifying intrauterine congestive heart failure, and impending hydrops endangering the fetal life. The absence of ductal flow between aorta and pulmonary artery is essential for the *in utero* survival of a fetus with APVS.

In fetuses with TOF, APVS, patent ductus arteriosus, and an unrestricted ventricular septal defect, the regurgitant flow from the aorta through ductus and absent pulmonary valve fills not only the right ventricle but also the left ventricle. The diastolic overload of both ventricles is probably incompatible with further fetal life and results in severe heart failure, fetal hydrops, and fetal loss.^{4,7–9} A possible additional

mechanism causing fetal demise could be a significant diastolic run-off not only from the systemic vascular bed of fetus but also from the critical placental vascular bed, leading ultimately to fetal hypoxaemia. In the present case, the presence of ductus made changes in fetal physiology leading to fetal heart failure (Figure 2A, E, and F).

In a study by Pinsky *et al.*,¹⁰ 40% of children with APVS had developed respiratory distress during early infancy secondary to aneurismal dilatation of pulmonary arteries compressing bronchi resulting in massive lobar emphysema. The most critical period for patients with APVS was in infancy. Autopsy done at neonatal death showed that ductus was almost always absent.⁴

Normally infundibulum is fairly short and vertical, whereas in APVS, the orientation of infundibulum can be towards right and horizontal with corresponding preferential aneurismal dilatation of right pulmonary artery, compressing the origin of the middle lobe bronchus, or left oriented with corresponding preferential aneurismal dilatation of left pulmonary artery, compressing left main bronchus and left upper lobe bronchus.¹¹ In our case, infundibulum was left oriented.

The severity of the heart disease, pulmonary complications, long-term medical management, complications of staged surgical interventions, and outcomes need to be explained to the parents. The possibility of developing intrauterine heart failure and hydrops in APVS should also be explained to the parents. Deletions in chromosome 22q1.2 in most of the patients with APVS were studied by Johnson *et al.*¹² This supports a specific genetic and embryologic mechanism involving the interaction of the neural crest and primitive aortic arches as a possible cause of APVS.

The prenatal diagnosis of APVS may be possible with a high degree of accuracy with characteristic fetal echocardiographic findings such as 'bow tie'-like or 'ballooning'-like shadows observed in this case. The presence of ductus confirms definite fetal loss and the parents can be counselled accordingly. However when the ductus is absent, decision making is difficult as the fetus is going to survive. Further studies on APVS may be required with respect to natural courses, survival of fetus with or without PDA, and outcomes of medical and surgical management in APVS for a reasonable prenatal counselling influences the decision of medical termination.

Conflict of interest: None declared

References

- Cheevers N. Raaetraaerissement congenital de l'orifice pulmonaire. *Arch Med Fourth Series* 1847;**15**:488.
- Mc Caughan BC, Danielson GK, Driscoll DJ, Mc Goon DC. Tetralogy of Fallot with absent pulmonary valve. Early results of surgical treatment. *J Thorac Cardiovasc Surg* 1985;**89**:280–7.
- Kirklin JW, Barratt-Boyes BG. Chapter 24: ventricular septal defect and pulmonary stenosis or atresia. In: Kouchoyos NT, Black Stone EH, Doty DB, Harley FL, Karp RB, eds. *Cardio Surgery*. 3rd ed. New York: Churchill Livingstone; 2003. p.961.
- Emanouilides GC, Jhanopoulos B, Siassi B, Fishbein M. Agenesis of ductus arteriosus associated with the syndrome of tetralogy of Fallot and absent pulmonary valve. *Am J Cardiol* 1976;**37**:403–09.
- Allan LD, Sharland GK, Milburn A, Lockhart SM, Groves AM, Anderson RH *et al.* Prospective diagnosis of 1,006 consecutive cases of congenital heart disease in the fetus. *J Am Coll Cardiol* 1994;**23**:1452–58.
- Tometzki AJ, Suda K, Kohl T, Kovalchin JP, Silverman NH. Accuracy of prenatal echocardiographic diagnosis and prognosis of fetuses with conotruncal anomalies. *J Am Coll Cardiol* 1999;**33**:1696–701.

7. Berg C, Thomsen Y, Geipel A, Germer U, Gembruch U. Reversed end diastolic flow in the umbilical artery at 10-14 wks GA is associated with APVS. *Ultrasound Obstet Gynecol* 2007;**30**:254–58.
8. Ettendgui JA, Sharland GK, Chita SK, Cook A, Fagg N, Allan LD. Absent pulmonary valve syndrome with ventricular septal defect: role of arterial duct. *Am J Cardiol* 1990;**66**:233–34.
9. Zach M, Beitzke A, Singer H, Hofler H, Schellmann B. The syndrome of absent pulmonary valve and ventricular septal defect-anatomical features and embryological implications. *Basic Res Cardiol* 1979;**74**:54–68.
10. Pinsky WW, Nihill MR, Mullins CE, Harrison G, McNamara DG. The absent pulmonary valve syndrome considerations of management. *Circulation* 1978;**57**:159–62.
11. Lakier JB, Stanger P, Heymann MA, Hoffman JJE, Rudolph AM. Tetralogy of Fallot with absent pulmonary valve, natural history and hemodynamic considerations. *Circulation* 1974;**50**:167–74.
12. Johnson MC, Strauss AVW, Downton SB, Spray TL, Huddleston CB, Wood MK *et al*. Deletion within chromosome 22 is common in patients with absent pulmonary valve syndrome. *Am J Cardiol* 1995;**76**:66–9.