

# Accuracy and reproducibility of left ventricular outflow tract diameter measurement using transthoracic when compared with transesophageal echocardiography in systole and diastole

Avinoam Shiran\*, Salim Adawi, Majdi Ganaeem, and Ehab Asmer

Department of Cardiovascular Medicine, Lady Davis Carmel Medical Center Israel, Ruth and Bruce Rappaport Faculty of Medicine, Technion-Israel Institute of Technology, 7 Michal Street, Haifa 34362, Israel

Received 13 March 2008; accepted after revision 10 September 2008; online publish-ahead-of-print 2 October 2008

## KEYWORDS

Left ventricular outflow tract;  
Aortic stenosis;  
Continuity equation;  
Transthoracic  
echocardiography;  
Transesophageal  
echocardiography

**Aims** Accurate measurement of left ventricular outflow tract diameter (LVOTd) is essential for reliable estimation of aortic valve area (AVA) using the continuity equation. Transesophageal echocardiography (TEE) can accurately delineate the LVOT. The aim of this study was to assess the accuracy and reproducibility of LVOTd measurement using transthoracic echocardiography (TTE) with harmonic imaging when compared with TEE, in both systole and diastole.

**Methods and results** We prospectively studied 50 patients [20 with aortic stenosis (AS) and 30 without AS]. LVOTd was measured offline in a blinded fashion in both systole and diastole by two experienced observers using TTE in the parasternal long axis view and TEE in the mid-oesophageal aortic view ( $\sim 130^\circ$ ). There was strong correlation between TTE and TEE ( $r = 0.91$ ). LVOTd was slightly smaller by TTE when compared with TEE ( $2.11 \pm 0.21$  vs.  $2.16 \pm 0.22$  cm, mean difference  $-0.05 \pm 0.09$  cm,  $P = 0.0003$ ). Compared with TEE, 95% (2SD) of LVOTd measurements by TTE were within  $+0.14$  and  $-0.24$  cm. Inter- and intra-observer variability for LVOTd was  $4.8 \pm 4.1$  and  $2.8 \pm 1.9\%$  for TTE and  $4.2 \pm 3.1$  and  $2.5 \pm 1.6\%$  for TEE ( $P = 0.4$  and  $0.6$ ). In patients with AS, estimated AVA was  $0.93 \pm 0.22$  cm<sup>2</sup> using TTE and  $0.96 \pm 0.24$  cm<sup>2</sup> using TEE,  $P = 0.08$ . Diastolic LVOTd by TEE was slightly smaller compared with systolic LVOTd by TEE ( $-0.03 \pm 0.07$  cm,  $P = 0.0005$ ), and there was strong correlation between the two ( $r = 0.95$ ).

**Conclusion** We present the data regarding accuracy and reproducibility of LVOTd measurements by TTE when compared with TEE. LVOTd measurements at end-diastole may be helpful when systolic images are suboptimal.

## Introduction

The non-invasive echocardiographic evaluation of patients with aortic stenosis (AS) routinely involves aortic valve area (AVA) estimation using the continuity equation.<sup>1</sup> The continuity equation has been validated in a variety of clinical and *in vitro* studies.<sup>2–11</sup>

Continuity equation:

$$AVA = \frac{CSA_{LVOT} \times TVI_{OT}}{TVI_{AS}},$$

where  $CSA_{LVOT}$  is the left ventricular outflow tract cross-sectional area,  $TVI_{OT}$  time-velocity integral of the

outflow tract flow, and  $TVI_{AS}$  time-velocity integral of the aortic flow.

Outflow tract and aortic velocities ( $V_{OT}$  and  $V_{AS}$ ) can be used instead of  $TVI_{OT}$  and  $TVI_{AS}$  with little effect on the accuracy of AVA estimation.<sup>1,7</sup>  $CSA_{LVOT}$  is calculated using the formula  $Area = \pi r^2$  where  $r$  is half of the left ventricular outflow tract diameter (LVOTd) measured from the parasternal long axis view, assuming a circular shape of the LVOT. LVOT area can be measured directly using three-dimensional (3D) echocardiography, computerized tomography (CT), or magnetic resonance imaging (MRI); however, 3D echocardiography has currently limited spatial resolution and CT and MRI are impractical for routine assessment of AS.

Although initial studies reported excellent accuracy and reproducibility of the continuity equation, its performance

\* Corresponding author. Tel: +972 4 825 0507; fax: +972 4 834 3755.  
E-mail address: shiranad@012.net.il

was not as good in later reports and LVOTd measurement is considered the weakest link in AVA estimation.<sup>3-5,9,11,12</sup> Because the radius is squared, small errors in LVOTd measurement will be compounded, especially when the LVOTd is small. Transesophageal echocardiography (TEE) allows excellent view of the LVOT and accurate measurement of the LVOTd.<sup>13</sup> Although systolic measurements of the LVOTd should be used in the continuity equation, in some patients the LVOT is difficult to image in systole using TTE, whereas it is clearly seen at the end of diastole. There is very little data, however, regarding the correlation between systolic and diastolic LVOTd measurements. The purpose of this study was to assess accuracy and reproducibility of LVOTd measurements using TTE by comparing them with TEE measurements, and compare diastolic with systolic LVOTd measurements.

Methods

Patient population

We prospectively studied 50 patients referred for TEE using TTE and TEE. Patients were referred for TEE for various clinical indications (Table 1). We enrolled in the study 20 consecutive patients with AS. We also enrolled 30 patients without AS referred for TEE during the study period, which constituted all the patients in whom TEE was performed by one of us (AS or SA) in the echocardiography laboratory on a non-emergency basis. In each of these 50 patients, the LVOT was carefully studied, prospectively, for the purpose of the present study. Patients with prosthetic valves or subaortic obstruction were excluded from the study. None of the patients were excluded because of poor image quality.

Echocardiography

Transthoracic echocardiography was performed using second harmonic imaging and a commercially available echocardiographic system (Sonos 5500, Agilent Technologies, Palo Alto, CA, USA) and a 1–3 MHz broadband transducer. A complete echocardiographic study was performed using standard views and techniques. The LVOT was imaged from the parasternal long axis view using harmonic imaging. Special care was taken to maximize LVOT diameter, using the imaging plane which bisects the circular LVOT through its true diameter, and to optimize the image for best LVOT border delineation. Magnified cine-loops of the LVOT area were digitally stored for offline analysis. In patients with AS, LVOT flow velocity was measured from the apical view using pulsed wave Doppler, and maximal aortic velocity was measured using continuous Doppler

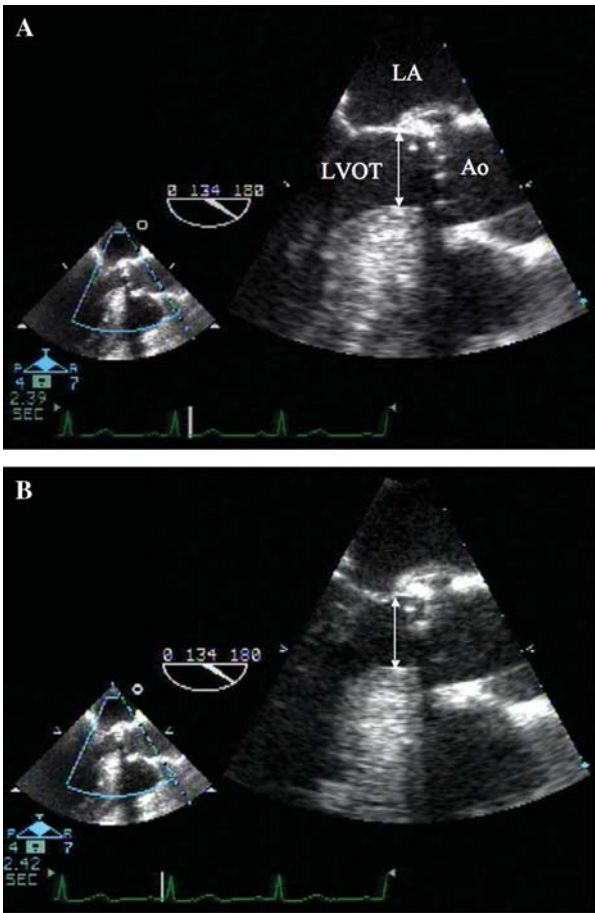
from the apical, suprasternal, and right sternal views as previously described, and the maximal velocity recorded.<sup>4</sup>

A complete TEE examination was performed using a multiplane broadband (4–7 MHz) TEE probe and the same ultrasound machine. The LVOT was imaged from the mid-oesophageal position in the longitudinal aortic view usually at ~130°. The aortic valve was positioned in the middle with the ascending aorta horizontal, maximizing the LVOT diameter (Figure 1). Magnified TEE cine-loops of the LVOT area were digitally stored for offline analysis.

The LVOTd was measured offline from the TTE and TEE cine-loops by two experienced echocardiographers in a blinded fashion (TTE vs. TEE). First, the LVOTd was measured at mid-systole just below the insertion of the aortic valve leaflets (Figure 1A).<sup>6</sup> Second, the LVOTd was measured at the end of diastole just before the aortic valve opening, in a blinded fashion (systole vs. diastole), more than 1 month after the systolic measurements (Figure 1B). For each measurement, three cardiac cycles were recorded and averaged. Final LVOTd measurements were the average of the two observers. Intra-observer variability was assessed in 10 consecutive patients by repeating the measurements by the two observers at least 1 month after the initial analysis. The AVA was calculated using the continuity equation from LVOTd data derived from TTE or TEE, and the Doppler data derived from TTE.

Statistical analysis

Continuous variables are presented as means ± SD, and compared using paired or unpaired *t*-test as appropriate. TTE and TEE

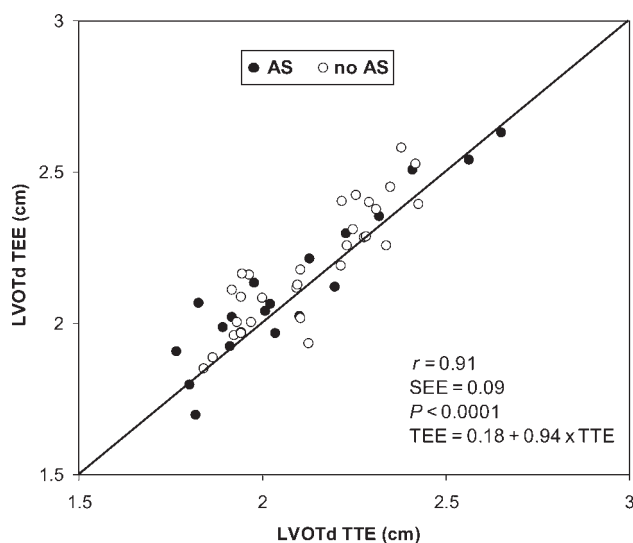


**Figure 1** Measurement of left ventricular outflow tract diameter (arrow) in a patient with severe aortic stenosis using transesophageal echocardiography from the mid-oesophageal view at 134°. (A) In mid-systole. (B) At the end of diastole. Ao, aorta; LA, left atrium; LVOT, left ventricular outflow tract.

**Table 1** Patient characteristics

	AS	No AS	All patients
<i>n</i>	20	30	50
Age (year)	78 ± 9	62 ± 13	69 ± 14
Gender, males (%)	5 (25)	18 (60)	23 (46)
Atrial fibrillation	12 (60%)	4 (13%)	16 (32%)
Lung disease	2 (10%)	2 (7%)	4 (8%)
Indication for TEE			
ASD	1 (5%)	1 (3%)	2 (4%)
Pre-cardioversion	7 (35%)	4 (13%)	11 (22%)
CSOE	1 (5%)	15 (50%)	16 (32%)
Suspected endocarditis	11 (55%)	10 (33%)	21 (42%)

AS, aortic stenosis; ASD, atrial septal defect; CSOE, cardiac source of embolism; TEE, transesophageal echocardiography.



**Figure 2** Correlation between systolic transthoracic and transeophageal echocardiography measurements of left ventricular outflow tract diameter. Patients with aortic stenosis (AS) are represented by filled circles, and patients without AS by open circles.

measurements of LVOTd and AVA were compared using Bland-Altman plots and correlated using linear regression analysis.<sup>14</sup> Inter- and intra-observer variability was determined as absolute difference divided by the average of the two measurements, and mean difference  $\pm$  SD.<sup>15</sup> Differences were considered statistically significant at the two-sided  $P < 0.05$  level.

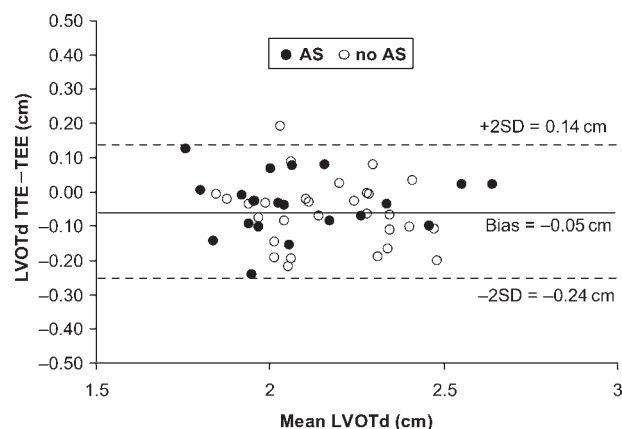
## Results

The patient characteristics are summarized in *Table 1*.

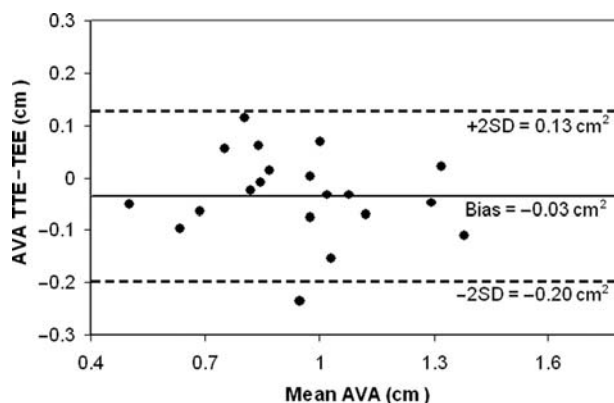
### Systolic LVOTd measurement by TTE vs. TEE

Left ventricular outflow tract diameter was slightly smaller when measured by TTE when compared with TEE,  $2.11 \pm 0.21$  vs.  $2.16 \pm 0.22$  cm, mean difference  $-0.05 \pm 0.09$  cm,  $P = 0.0003$ . There was strong correlation in LVOTd measurements between TTE and TEE (*Figure 2*). Bland-Altman plot shows the agreement and  $\pm 2$ SD (95%) limits for LVOTd measurements by TTE when compared with TEE (*Figure 3*). The agreement between TTE and TEE measurements was similar for patients with small LVOTd and patients with large LVOTd, and for patients with AS and patients without AS. The difference between TTE and TEE measurements was  $-0.06 \pm 0.09$  cm for patients with an optimal TTE window ( $n = 40$ ,  $r = 0.92$ ) and  $-0.014 \pm 0.12$  cm for patients with a suboptimal TTE window ( $n = 10$ ,  $r = 0.87$ ).

In patients with AS ( $n = 20$ ), LVOTd was  $2.08 \pm 0.25$  cm by TTE and  $2.11 \pm 0.25$  cm by TEE, mean difference  $-0.04 \pm 0.09$  cm,  $P = 0.08$ . Estimated AVA using the continuity equation was  $0.93 \pm 0.22$  cm<sup>2</sup> using TTE measured LVOTd and  $0.96 \pm 0.24$  cm<sup>2</sup> using TEE measured LVOTd,  $P = 0.08$ . Bland-Altman plot shows the agreement and  $\pm 2$ SD (95%) limits for AVA measurements using TTE derived LVOTd vs. TEE derived LVOTd (*Figure 4*). The definition of severe AS ( $AVA \leq 1$  cm<sup>2</sup>) was discordant between TTE and TEE in two patients (10%).



**Figure 3** Bland-Altman plot showing the difference in left ventricular outflow tract diameter measurements between transthoracic and transeophageal echocardiography. Solid line represents mean difference (or bias), and broken lines represent  $\pm 2$  standard deviations or  $\pm 95\%$  scatter. Patients with aortic stenosis (AS) are represented by filled circles, and patients without AS by open circles.

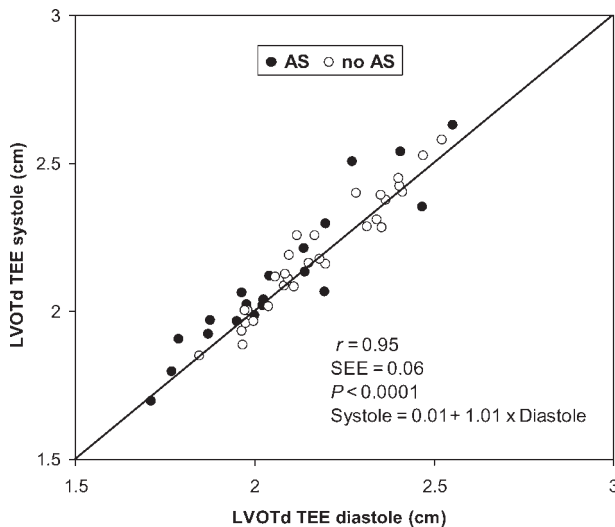


**Figure 4** Bland-Altman plot showing the difference in estimated aortic valve area based on left ventricular outflow tract diameter measurements using transthoracic vs. transeophageal echocardiography, in the patients with aortic stenosis. Solid line represents mean difference (or bias), and broken lines represent  $\pm 2$  standard deviations or  $\pm 95\%$  scatter.

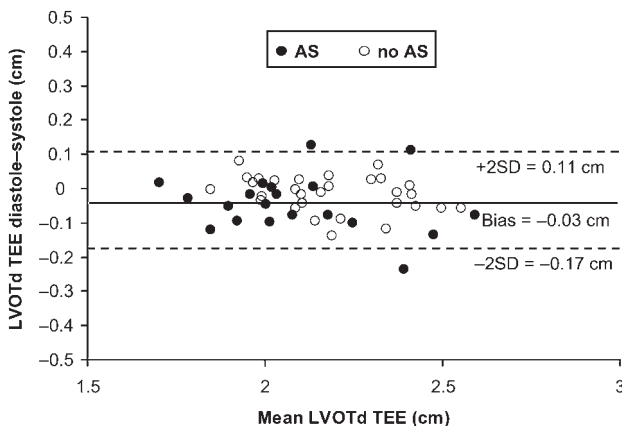
### Systolic vs. diastolic LVOTd measurements

There was a strong correlation between systolic and diastolic LVOTd measurements [ $r = 0.95$  for TEE (*Figure 5*) and  $r = 0.92$  for TTE]. LVOTd as measured by TEE was slightly smaller during diastole when compared with systole ( $2.13 \pm 0.21$  vs.  $2.16 \pm 0.22$  cm, mean difference  $-0.03 \pm 0.07$  cm,  $P = 0.0005$ ). Bland-Altman plot shows the agreement and  $\pm 2$ SD (95%) limits for diastolic and systolic TEE measurements of LVOTd (*Figure 6*). When measured by TTE, LVOTd was  $2.10 \pm 0.18$  cm during diastole and  $2.11 \pm 0.21$  cm during systole, mean difference  $-0.02 \pm 0.08$  cm,  $P = 0.2$ . The agreement between systolic and diastolic measurements was similar for patients with AS and patients without AS.

Estimated AVA using the continuity equation was  $0.92 \pm 0.22$  cm<sup>2</sup> using diastolic and  $0.96 \pm 0.24$  cm<sup>2</sup> using systolic LVOTd measurements by TEE (mean difference  $-0.04 \pm 0.08$  cm,  $P = 0.04$ ), and  $0.93 \pm 0.22$  and  $0.90 \pm 0.20$  cm<sup>2</sup> by TTE,  $P = 0.2$ . Bland-Altman plot shows



**Figure 5** Correlation between diastolic and systolic transesophageal echocardiography measurements of left ventricular outflow tract diameter. Patients with aortic stenosis (AS) are represented by filled circles, and patients without AS by open circles.



**Figure 6** Bland-Altman plot showing difference between diastolic and systolic transesophageal echocardiography measurements of the left ventricular outflow tract diameter. Solid line represents mean difference (or bias), and broken lines represent  $\pm 2$  standard deviations or  $\pm 95\%$  scatter. Patients with aortic stenosis (AS) are represented by filled circles, and patients without AS by open circles.

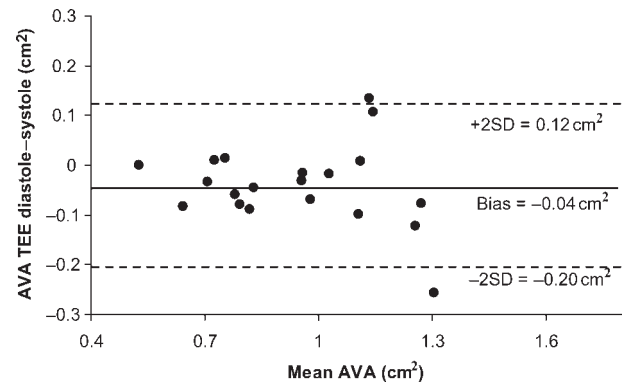
the agreement and  $\pm 2SD$  (95%) limits for AVA measurements using diastolic vs. systolic TEE derived LVOTd (Figure 7). The definition of severe AS ( $AVA \leq 1 \text{ cm}^2$ ) was concordant between diastolic and systolic TEE derived LVOTd in all patients, and discordant between diastolic and systolic TTE derived LVOTd in two patients.

### Reproducibility of LVOTd measurements

Inter- and intra-observer variability for LVOTd measurements is presented in Table 2.

### Discussion

Earlier studies using older equipment without harmonic imaging and selected patients reported strong correlation



**Figure 7** Bland-Altman plot showing difference in estimated aortic valve area based on left ventricular outflow tract diameter measurements using diastolic vs. systolic transesophageal echocardiography images in patients with aortic stenosis. Solid line represents mean difference (or bias), and broken lines represent  $\pm 2$  standard deviations or  $\pm 95\%$  scatter.

between echocardiographic derived AVA using the continuity equation and catheterization derived AVA using the Gorlin formula ( $r = 0.89\text{--}0.92$ ).<sup>2,8</sup> Newer studies evaluating accuracy of TEE derived AVA using planimetry of the aortic valve reported less optimal correlation ( $r = 0.66\text{--}0.7$ ) between the same two measurement methods.<sup>3,5</sup> Reproducibility of the continuity equation was questioned, especially with regard to LVOTd measurements ( $r = 0.36$ ).<sup>12</sup> Using TEE as a reference in a representative population of unselected patients, we found that TTE slightly underestimated LVOTd by an average of 0.5 mm (Figures 2–4). This small difference is probably unimportant clinically.

Although inter- and intra-observer variability with TEE was better when compared with TTE, the difference was not statistically significant, and compared well with older studies (inter-observer variability was 6% in the study of Lewis *et al.* vs.  $4.8 \pm 4.1\%$  in the present study).<sup>6</sup> Furthermore, the standard deviation of TTE vs. TEE measurements (Figure 3) was smaller than the inter-observer variability using TEE ( $\pm 0.09$  vs.  $\pm 0.11$  cm). Although subaortic calcification can make LVOTd measurements more difficult, we found no difference in the accuracy of LVOTd measurements by TTE when compared with TEE in patients with AS compared with patients without AS (Figures 2 and 3). Such subvalvular calcifications should probably be ignored when measuring LVOTd.<sup>8</sup> We also found no significant difference in the absolute error of LVOTd measurements between smaller and larger LVOTd values, but the same error in a smaller LVOTd will result a larger error in the final AVA estimation.

### Diastolic LVOTd measurements

Traditionally, LVOTd measurements are made in mid-systole, at the same time during the cardiac cycle the LVOT flow velocity measurements are made.<sup>1,2,4,7,9,11</sup> In some of the patients, image quality is suboptimal during systole and the LVOT is not clearly delineated, whereas it is clearly seen and easily measured at the end of diastole (Figure 1B). Liv Hatle<sup>8</sup> suggested more than 20 years ago that the LVOTd can be measured at the end of diastole, based on a small study involving 10 patients and showing no significant difference between mean systolic and



Table 2 Reproducibility of left ventricular outflow tract diameter measurements

	Intra-observer variability		Inter-observer variability	
Systole				
TTE	2.8 ± 1.9% (0.35–11%)	0.01 ± 0.08 cm*	4.8 ± 4.1% (0.15–18%)**	0.05 ± 0.12 cm
TEE	2.5 ± 1.6% (0.52–6.9%)	0.03 ± 0.06 cm*	4.2 ± 3.1% (0.15–12%)**	0.03 ± 0.11 cm
Diastole				
TTE			6.6 ± 4.9% (0.14–21%)***	0.11 ± 0.15 cm
TEE			5.2 ± 4.6% (0–17%)***	0.06 ± 0.14 cm

\**P* = 0.6, \*\**P* = 0.4, \*\*\**P* = 0.2 for TTE vs. TEE.  
TEE, transesophageal echocardiography; TTE, transthoracic echocardiography.

diastolic LVOTd measurements.<sup>16</sup> In this study, using high-quality TEE images, we found strong correlation between systolic and diastolic LVOTd measurements (*Figure 5*). Diastolic LVOTd by TEE was slightly smaller than systolic LVOTd (0.03 cm), but this small difference resulted in a small difference in AVA which is not clinically important. The reason for the lack of change between systole and diastole is the relatively rigid aortic valve annulus.<sup>17</sup>

## Study limitations

LVOT area and AVA were not measured directly in this study, for lack of a true 'gold standard'. CT or MRI, methods that can measure directly the LVOT area, was not used in this study. The assumption that the LVOT shape is circular was also challenged.<sup>18</sup> Direct measurement of AVA using TEE has limitations, and the limitations of AVA calculations using cardiac catheterization and the Gorlin formula are well known.<sup>3,5,8,19</sup> Spevack *et al.*<sup>20</sup> found wide variation between AVA using the continuity equation and catheterization derived AVA, even after correction for pressure recovery. TEE, however, is an excellent modality to study the LVOT with high-resolution, unobstructed images using the best axial resolution from an ultrasound beam which is perpendicular to the LVOT borders. Fan *et al.*<sup>13</sup> have shown strong correlation between LVOTd and the aortic homograft selected for the patients. We found TEE LVOTd measurements to be highly reproducible.

Inter- and intra-observer variability included only the measurement component and not the recording component of LVOTd, and the combined variability could be somewhat greater. Nevertheless, the correlation between TTE and TEE measurements, which included also the recording component, was excellent.

Patients with prosthetic valves were not included in this study, and our findings may not apply to patients with prosthetic valves.

### Clinical implications for LVOTd measurements

The present data can aid sonographers and physicians in several ways. TEE derived LVOTd can be used as a reference while training inexperienced personnel. When image quality is suboptimal during systole and the LVOT is clearly seen at the end of diastole, LVOTd measurement at the end of diastole may be helpful. In the few patients with an unacceptable parasternal acoustic window, TEE can be used both for planimetry of AVA and for accurate measurement of LVOTd to be used with TTE or TEE derived

Doppler data in the continuity equation. Last, this data can be used to estimate the LVOTd-related error and confidence interval of AVA estimation using the continuity equation.

The final decision whether or not to send the patient for surgery should depend heavily on the patient's symptoms as well as other clinical and echocardiographic parameters, such as aortic valve calcification and leaflet mobility, *trans*-aortic gradients and left ventricular function.<sup>21</sup> AVA, although important, is just one parameter in the final decision.

**Conflict of interest:** none declared.

## References

1. Feigenbaum HAW, Ryan T. *Feigenbaum's Echocardiography*. 6 ed. Lippincott: Williams & Wilkins; 2005.
2. Grayburn PA, Smith MD, Harrison MR, Gurley JC, DeMaria AN. Pivotal role of aortic valve area calculation by the continuity equation for Doppler assessment of aortic stenosis in patients with combined aortic stenosis and regurgitation. *Am J Cardiol* 1988;**61**:376-81.
3. Cormier B, Lung B, Porte JM, Barbant S, Vahanian A. Value of multiplane transesophageal echocardiography in determining aortic valve area in aortic stenosis. *Am J Cardiol* 1996;**77**:882-5.
4. Harrison MR, Gurley JC, Smith MD, Grayburn PA, DeMaria AN. A practical application of Doppler echocardiography for the assessment of severity of aortic stenosis. *Am Heart J* 1988;**115**:622-8.
5. Kim KS, Maxted W, Nanda NC, Coggins K, Roychoudhry D, Espinal M *et al*. Comparison of multiplane and biplane transesophageal echocardiography in the assessment of aortic stenosis. *Am J Cardiol* 1997;**79**:436-41.
6. Groves PH, Lewis NP, Ikram S, Maire R, Hall RJ. Reduced exercise capacity in patients with tricuspid regurgitation after successful mitral valve replacement for rheumatic mitral valve disease. *Br Heart J* 1991;**66**:295-301.
7. Oh JK, Taliercio CP, Holmes DR Jr, Reeder GS, Bailey KR, Seward JB *et al*. Prediction of the severity of aortic stenosis by Doppler aortic valve area determination: prospective Doppler-catheterization correlation in 100 patients. *J Am Coll Cardiol* 1988;**11**:1227-34.
8. Skjaerpe T, Hegrenaes L, Hatle L. Noninvasive estimation of valve area in patients with aortic stenosis by Doppler ultrasound and two-dimensional echocardiography. *Circulation* 1985;**72**:810-8.
9. Teirstein P, Yeager M, Yock PG, Popp RL. Doppler echocardiographic measurement of aortic valve area in aortic stenosis: a noninvasive application of the Gorlin formula. *J Am Coll Cardiol* 1986;**8**:1059-65.
10. Tribouilloy C, Shen WF, Peltier M, Mirode A, Rey JL, Lesbre JP. Quantitation of aortic valve area in aortic stenosis with multiplane transesophageal echocardiography: comparison with monoplane transesophageal approach. *Am Heart J* 1994;**128**:526-32.
11. Zoghbi WA, Farmer KL, Soto JG, Nelson JG, Quinones MA. Accurate noninvasive quantification of stenotic aortic valve area by Doppler echocardiography. *Circulation* 1986;**73**:452-9.
12. Geibel A, Gornandt L, Kasper W, Bubenheimer P. Reproducibility of Doppler echocardiographic quantification of aortic and mitral valve

- stenoses: comparison between two echocardiography centers. *Am J Cardiol* 1991;**67**:1013–21.
13. Fan CM, Liu X, Panidis JP, Wiener DH, Pollack PS, Addonizio VP. Prediction of homograft aortic valve size by transthoracic and transesophageal two-dimensional echocardiography. *Echocardiography* 1997;**14**:345–8.
  14. Bland JM, Altman DG. Statistical methods for assessing agreement between two methods of clinical measurement. *Lancet* 1986;**1**:307–10.
  15. Moller JE, Sondergaard E, Poulsen SH, Appleton CP, Egstrup K. Serial Doppler echocardiographic assessment of left and right ventricular performance after a first myocardial infarction. *J Am Soc Echocardiogr* 2001;**14**:249–55.
  16. Ihlen H, Amlie JP, Dale J, Forfang K, Nitter-Hauge S, Otterstad JE *et al.* Determination of cardiac output by Doppler echocardiography. *Br Heart J* 1984;**51**:54–60.
  17. Gnyaneshwar R, Kumar RK, Balakrishnan KR. Dynamic analysis of the aortic valve using a finite element model. *Ann Thorac Surg* 2002;**73**: 1122–9.
  18. Burgstahler C, Kunze M, Loffler C, Gawaz MP, Hombach V, Merkle N. Assessment of left ventricular outflow tract geometry in non-stenotic and stenotic aortic valves by cardiovascular magnetic resonance. *J Cardiovasc Magn Reson* 2006;**8**:825–9.
  19. Cannon SR, Richards KL, Crawford M. Hydraulic estimation of stenotic orifice area: a correction of the Gorlin formula. *Circulation* 1985;**71**: 1170–8.
  20. Spevack DM, Almuti K, Ostfeld R, Bello R, Gordon GM. Routine adjustment of Doppler echo cardiographically derived aortic valve area using a previously derived equation to account for the effect of pressure recovery. *J Am Soc Echocardiogr* 2008;**21**:34–7.
  21. Bonow RO, Carabello BA, Kanu C, de Leon AC Jr, Faxon DP, Freed MD *et al.* ACC/AHA 2006 guidelines for the management of patients with valvular heart disease: a report of the American College of Cardiology/American Heart Association Task Force on Practice Guidelines (writing committee to revise the 1998 Guidelines for the Management of Patients With Valvular Heart Disease): developed in collaboration with the Society of Cardiovascular Anesthesiologists: endorsed by the Society for Cardiovascular Angiography and Interventions and the Society of Thoracic Surgeons. *Circulation* 2006;**114**:e84–e231.