

Non-invasive diagnosis of coronary-subclavian steal: role of the Doppler ultrasound

J. Večeřa^{1*}, P. Vojtišek¹, I. Varvařovský², M. Lojík³, K. Mášová⁴, and J. Kvasnička⁵

¹Internal Clinic, Department of Cardiology, Regional Hospital Pardubice a.s, Pardubice, Czech Republic; ²Kardio-Troll s r.o, Regional Hospital Pardubice a.s, Pardubice, Czech Republic; ³Radiology Clinic, Department of Interventional Radiology, University Hospital Hradec Králové, Králové, Czech Republic; ⁴Department of Radiodiagnostics, Regional Hospital Pardubice a.s, Pardubice, Czech Republic; and ⁵Artur Koblitz, s.r.o., Invasive Arrhythmology Department, Regional Hospital Pardubice a.s, Pardubice, Czech Republic

Received 24 February 2010; accepted after revision 26 April 2010; online publish-ahead-of-print 22 May 2010

Coronary subclavian steal syndrome (CSSS) is a well documented cause of graft function failure in patients after left internal mammary artery (LIMA)—left anterior descending (LAD) coronary artery grafting. We present a case of the CSSS in a patient with cardiac arrest due to ventricular fibrillation. To our knowledge such a case has not yet been described. Patient with a history of LIMA—LAD grafting, complaining only of a mild chronic exertional dyspnoea developed ventricular fibrillation while walking outdoor. After successful resuscitation, blood pressure difference between both arms and abnormal LIMA flow with systolic reversal flow on the Doppler ultrasonography were suggestive of CSSS. Angiography proved the left subclavian artery (LSA) occlusion and coronary angiography confirmed reversal flow in the LIMA graft. Successful percutaneous transluminal angioplasty of the LSA re-established normal LIMA flow and improved the left ventricular hypokinesis and systolic function.

Keywords

Coronary-subclavian steal • Left mammary artery • Left anterior descending artery graft • Doppler ultrasonography

Case report

Sixty-eight-year-old male was admitted to the hospital after successful resuscitation of cardiac arrest with documented ventricular fibrillation.

Four years back, he had undergone coronary artery bypass grafting (CABG) when the left internal mammary artery (LIMA) was grafted to the left anterior descending artery (LAD) and saphenous vein conduits were grafted to the marginal branch of the circumflex artery and to the posterior descending artery. Six months later, the patient had recurrence of angina. On coronary angiography, the graft for the posterior interventricular artery was occluded and any intervention was deemed impossible. The LIMA—LAD bypass and the venous graft to the marginal branch of the circumflex artery were functioning well. His therapy was adjusted and since then he was all but asymptomatic, complaining only of mild exertional dyspnoea (NYHA II). The cardiac arrest which brought him to the hospital occurred during a leisure outdoor walk.

On admission, the physical examination revealed difference in systolic blood pressure between the left and right arm of 40 mmHg with other findings unremarkable. There was no bruit

in the left subclavicular region. Blood pressure (measured on the right arm) was 160/75 mmHg. There was no significant rise in cardiac markers after the cardiac arrest. On echocardiography, the left ventricle was enlarged and its systolic function compromised (40%). When compared with findings obtained 4 years ago, the anterolateral ventricular wall was hypokinetic. Doppler ultrasonography of the LIMA—LAD graft, with high-frequency linear probe (4 MHz) placed in the third left parasternal intercostal space, revealed a waveform highly suggestive of abnormal function: systolic reversal and minimal retrograde diastolic flow (Figure 1A). The Doppler waveform of the ungrafted right mammary artery was evaluated to serve as a control to compare the direction of the blood flow (Figure 1B). Ultrasound evaluation of the left subclavian artery (LSA) origin from the suprasternal projection was not feasible.

Aortic angiography revealed left subclavian (LSA) ostial occlusion. Right vertebral artery angiography showed no reverse flow under basal condition despite the undeniable signs of the coronary-subclavian steal. Injection of the contrast dye into the left coronary artery revealed a severe stenosis of the left main coronary artery (80% d.s.), non-stenotic LAD, and a retrograde flow in the LIMA—LAD graft (Figure 2A and B). The obtuse marginal

* Corresponding author. Tel: +42 77 786 9753, Email: janvecera24@yahoo.com

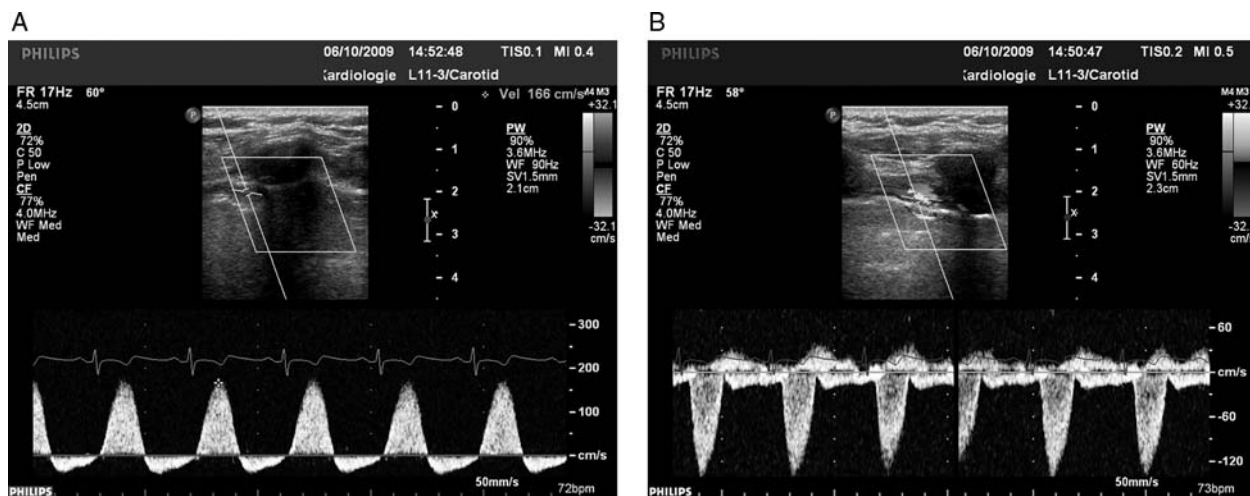


Figure 1 (A) Doppler ultrasound image of the proximal left mammary artery to left anterior descending artery graft prior left subclavian artery angioplasty; systolic reversal flow and mild diastolic orthograde flow is present. (B) Doppler ultrasound image of the proximal right mammary artery; normal arterial orthograde waveform contrasting with the opposite systolic direction of the flow in LIMA–LAD graft in (A).

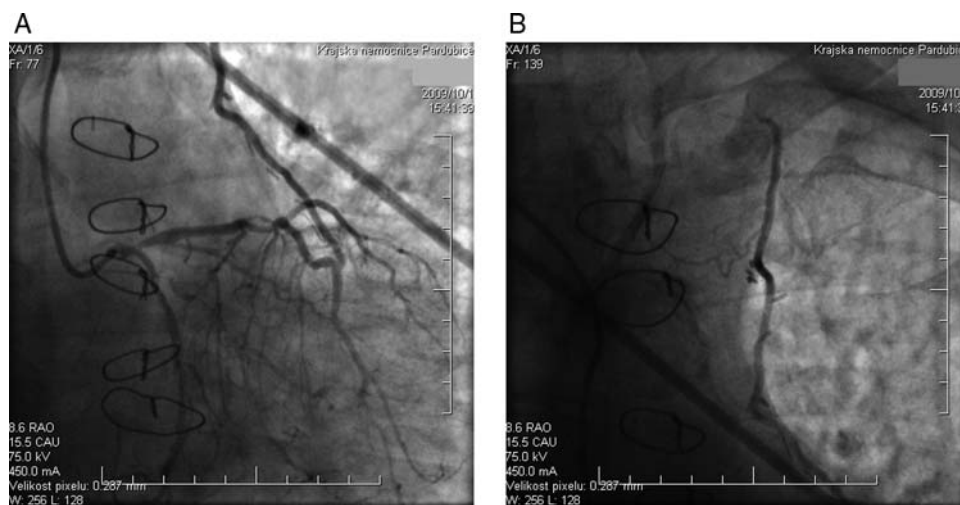


Figure 2 (A) Coronary angiogram of the left coronary artery showing left main stem stenosis and reverse filling of the LIMA–LAD graft. (B) Angiogram of the LIMA–LAD graft with the antegrade flow to the left subclavian artery.

branch of the left circumflex artery was occluded, and the venous graft to its periphery was functional. Origin of the right coronary artery was occluded and the venous graft to its periphery was obliterated.

Percutaneous transluminal angioplasty of LSA with implantation of two stents re-established normal arterial flow and normal flow in the LIMA–LAD graft (Figure 3A). The procedure was uneventful.

Echocardiography performed before discharge from the hospital showed nearly complete reversal of the hypokinesia of the anterolateral ventricular wall and improvement in its ejection fraction. Doppler ultrasound of the LIMA–LAD graft showed small systolic and prominent diastolic orthograde flow typical for patent LIMA–

LAD graft with peak diastolic to peak systolic velocity 1.4 (normal >0.8) (Figure 3B). Patient was discharged asymptomatic and in good condition.

Discussion

In patients with LIMA–LAD artery graft the CSSS refers to ‘stealing’ blood away from the LAD to the left arm due to severe proximal subclavian artery stenosis. Diversion of blood from the coronary circulation may result in angina and rarely in acute myocardial infarction. We report the case of a patient with history of the CABG who survived ventricular fibrillation, in whom occlusion

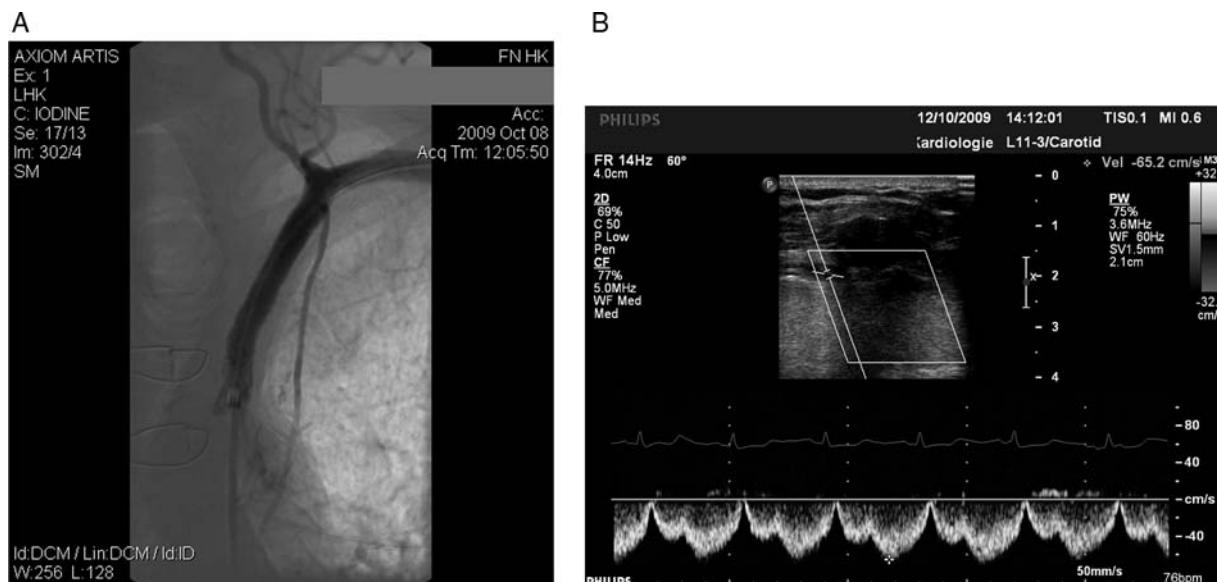


Figure 3 (A) Angiogram of the left subclavian artery (LSA) and its branches after successful angioplasty LSA with two stents; ortograde flow in LIMA–LAD graft and left vertebral artery is present. (B) Doppler ultrasound image of the proximal left mammary artery to left anterior descending artery graft after LSA angioplasty; small systolic and prominent diastolic ortograde flow indicating normal function of the patent LIMA–LAD graft (compare with Figure 1A).

of the LSA was demonstrated by aortic angiography, the reversal blood flow in the LIMA–LAD graft by Doppler ultrasonography and coronary angiography, but in whom ventricular fibrillation was the only clinical symptom of the coronary heart disease before the event. Although participation of the CSSS on the regional ventricular hypoperfusion initiating ventricular fibrillation remains only a hypothesis, restitution of the left ventricular hypokinesia and improvement of its systolic function shortly after successful stenting of the SCA give some support.

The incidence of CSSS seems to be anywhere between 0.5 and 15%.^{1,2} After successful LIMA–LAD grafting the CSSS should be considered whenever the patient develops anginal pains. The reversal flow in LIMA–LAD graft has been described during ipsilateral upper extremity exercise, but—just as demonstrated in our case—sometimes it can be identified even under basal conditions³ (Figure 1A).

Left-sided subclavian bruits on auscultation and difference in blood pressure readings on right and left arm should raise suspicion on the subclavian artery stenosis.

There are several diagnostic modalities used to detect subclavian artery stenosis, which is the former key condition of the CSSS, such as computed tomography angiography, the combination of magnetic resonance imaging, angiography, or duplex ultrasound imaging, which may reveal abnormal vertebral artery flow as a sign of vertebral artery subclavian steal.

The latter key point is LIMA function and reversal flow detection which can be detected with angiography considered as golden standard and with Doppler ultrasound.

Transthoracic Doppler ultrasound is a well-established bedside non-invasive method for IMA graft function evaluation.⁵ Evaluation of the *in situ* internal mammary artery (IMA) graft patency and

function is feasible in 90% patients.^{4–6} A patent grafted IMA with normal function bears flow characteristics of the grafted vessel (LAD) with small systolic and prominent diastolic ortograde flow, where the ratio between peak diastolic and peak systolic velocity should be >0.8 in grafted IMA with normal function (Figure 3B).

The un-grafted right internal mammary artery (RIMA) shows, on the contrary, arterial high-resistive Doppler waveform with prominent systolic flow (Figure 1B).

Evaluation of the un-grafted RIMA as a reference vessel may be very useful as it demonstrates the abnormality: the blood flow in systole is just opposite to what is expected in patent IMA graft with normal function (Figure 1A and B).

We believe that this simple and reliable technique may prove to be a valuable first-line tool in follow-up of all symptomatic patients with LIMA–LAD graft.

Conclusion

In patients who develop any symptom of the coronary heart disease after successful LIMA–LAD grafting, CSSS should be considered. In our patient, the only symptom of the coronary heart disease was ventricular fibrillation. Careful comparison of the blood pressure reading on the right and left arm and assessment of the LIMA–LAD coronary graft flow with Doppler ultrasonography may provide easily obtained clues to the correct diagnosis.

References

1. Tyras DH, Barner HB. Coronary-subclavian steal. *Arch Surg* 1977;**112**:1125–7.
2. Ferrara F, Meli F, Raimondi F, Milio G, Amato C, Cospite V et al. Subclavian stenosis/occlusion in patients with subclavian steal and previous bypass of internal mammary interventricular anterior artery: medical or surgical treatment? *Ann Vasc Surg* 2004;**18**:566–71.

3. Fitzgibbon GM, Kafka HP, Leach AJ, Keon Wj, Hooper GB, Burton JR. Coronary bypass graft fate and patient outcome: angiographic follow up of 5065 grafts related to survival and reoperation in 1388 patients during 25 years. *J Am Coll Cardiol* 1996;**28**:616–26.
4. Canver CC, Ricotta JJ, Bhayana JN, Fiedler RC, Mentzer RM Jr. Use of duplex imaging to assess suitability of the internal mammary artery for coronary artery surgery. *J Vasc Surg* 1991;**13**:294–301.
5. Meyer GP, Laudenberg B, Hausmann D, Mügge A, Cremer J, Hornig B et al. Transthoracic Doppler validation in mammary artery grafts after minimal invasive direct coronary artery bypass operation. *J Am Soc Echocardiogr* 2004;**17**: 954–61.
6. Chirillo F, Brunio A, Balestra G, Cavallini C, Olivari Z, Thomas JD et al. Assessment of internal mammary artery and saphenous vein graft patency and flow reserve using transthoracic Doppler echocardiography. *Heart* 2001;**86**:424–31.